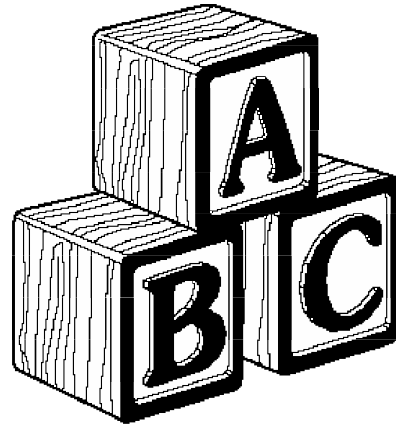


ABC's Blunt Chest Trauma

Jud W. Gurney MD FACR



www.chestx-ray.com

The ABC's of blunt chest trauma is a method to systematically evaluate the major injuries which occur in these individuals.

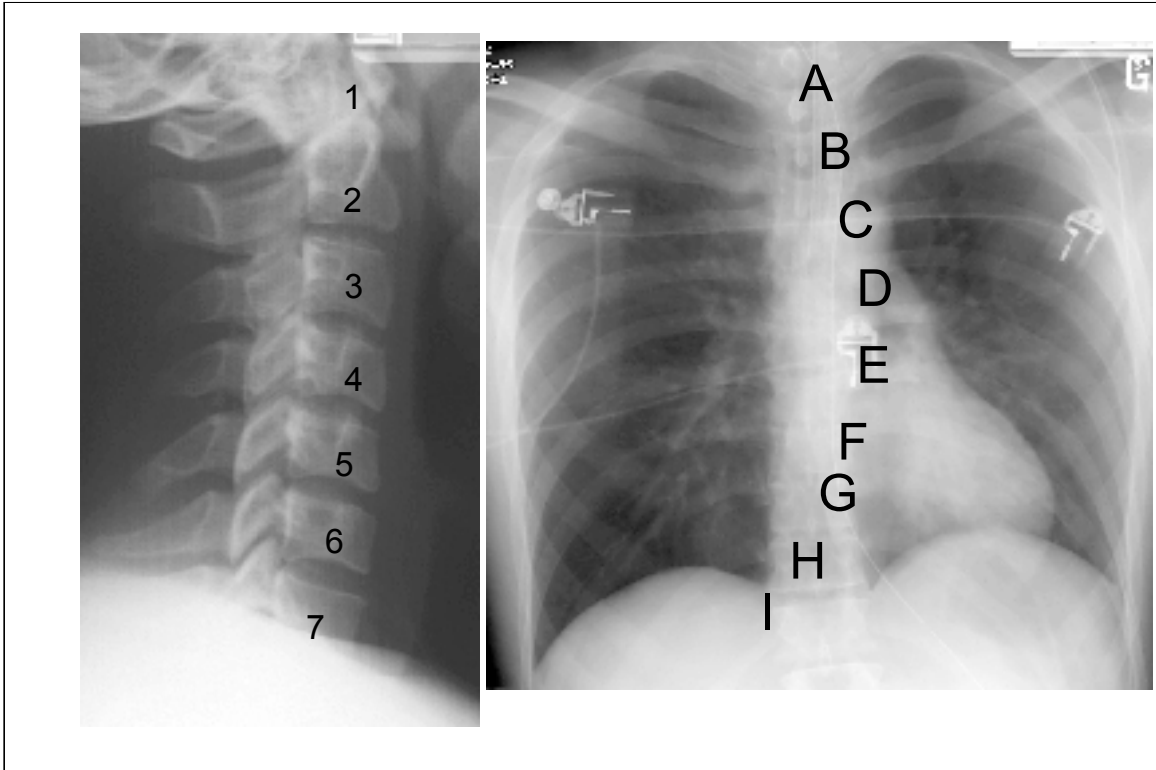
Objectives

ABC approach to chest x-ray

Role of CT in aortic transection

What follow-up exams to recommend if
screening chest x-ray abnormal

At the end of this lecture you should be able to answer the following objectives.



All of us learn to evaluate the cervical spine by counting the vertebral bodies. A similar approach can be used to evaluate the chest radiograph.

Delayed Diagnosis

> 30 days

Aortic Transection 5%

Bronchial Tear 40

Diaphragmatic Rupture 60

Misinterpretation is common even for the most serious injury. For some injuries, missing the injury is the rule not the exception.

Missed Diagnosis

4% Died within 24 hours

30% misinterpreted

Aortic tear

Diaphragm hernia

Flail segments

McLellan Can J Surg 1996

In a retrospective review of trauma patients that died within 24 hours of admission, 30% of the chest radiographs had been misinterpreted.

ABC's Approach

Aortic transection

Bronchial fracture

Cord injury

Diaphragm rupture

Esophageal tear

Flail chest

Gas (pneumothorax)

Heart (cardiac injury)

Iatrogenic misplaced tubes & catheters

Similar to the ABC's of clinical management: Airway, breathing and circulation, these are the ABC's of radiographic evaluation.

Caveats

Satisfaction of search

Subtle signs

Screen!

Keep these principles in mind, as we progress through the ABC's. Using the ABC's will help you avoid satisfaction of search. The signs of some of these injuries may be subtle. As you'll see, it is easy to overlook a serious injury especially in the presence of a more obvious abnormality elsewhere. Finally the chest x-ray is a screening exam, rarely is it diagnostic of an injury. Rather the presence of an injury must be confirmed by other tests which I will emphasize as we proceed.

Clinical Prediction Rule

The screenshot shows a web-based calculator titled "Injury Prediction Rule". It features a list of clinical criteria with checkboxes: "Age > 50" (checked), "Unrestrained" (unchecked), "Hypotension" (unchecked), "Thoracic Injury" (unchecked), "Abdominopelvic Injury" (unchecked), "Blunt Injury to Chest" (checked), and "Head Injury" (checked). Below the list are two buttons: "Calculate Probability" and "Reset". The result area displays: "The Probability of Aortic Rupture is 4.5% (1.4 - 7.9%). Computed Tomography (CT) is more effective for evaluation of the aorta." At the bottom, a small text box reads: "Frequency of Aortic Rupture in Blunt Chest Trauma Studies (n=1772 pts), prevalence 1.4% (0.2 - 2.5%) from [link]"

Blackmore AJR 2000

Although this lecture is concerned with blunt chest trauma, the victim has sustained violent forces that affect multiple other organs. As you can see, aortic injury usually occurs with multiple other injuries. Before we consider aortic trauma, it is important to keep in mind that rarely is this an isolated injury. As you can see, aortic injury usually occurs with multiple other injuries. An interactive version of this prediction rule is available elsewhere on this web site.



Traumatic Aortic Rupture

16% MVA fatalities

85 - 90% mortality prior to reaching hospital

Survivors

30% die within 6 hours

50% die within 24 hours

72% die within 8 days

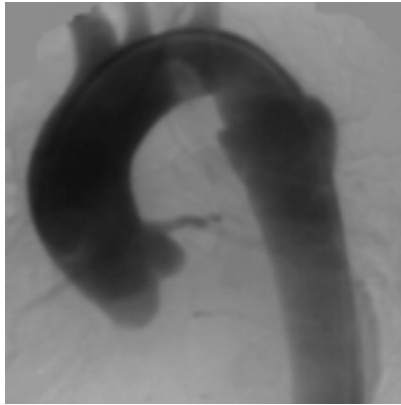
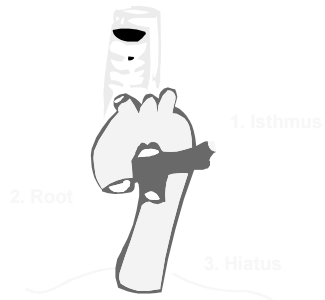
90% die within 4 months

It's only fitting that the ABC's begin with the most serious injury: aortic transection. In the past, all transections were immediately repaired when discovered. Only recently have surgeons learned that acute surgery is not always necessary. With control of blood pressure and close radiographic follow-up, surgery may be delayed and many patients remain alive for years with chronic pseudoaneurysms.

Traumatic rupture aorta

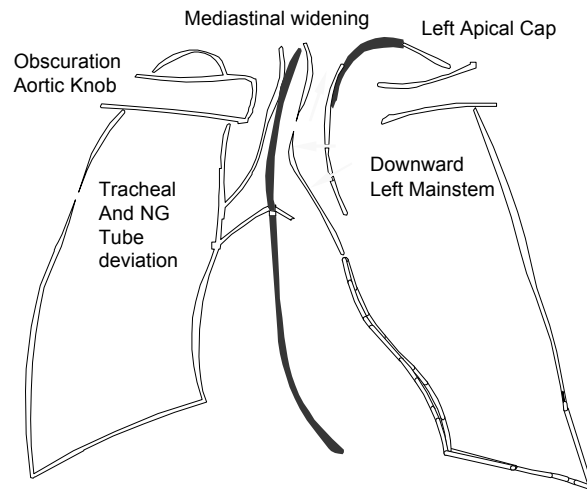
90% Aortic isthmus

4% Arch branches

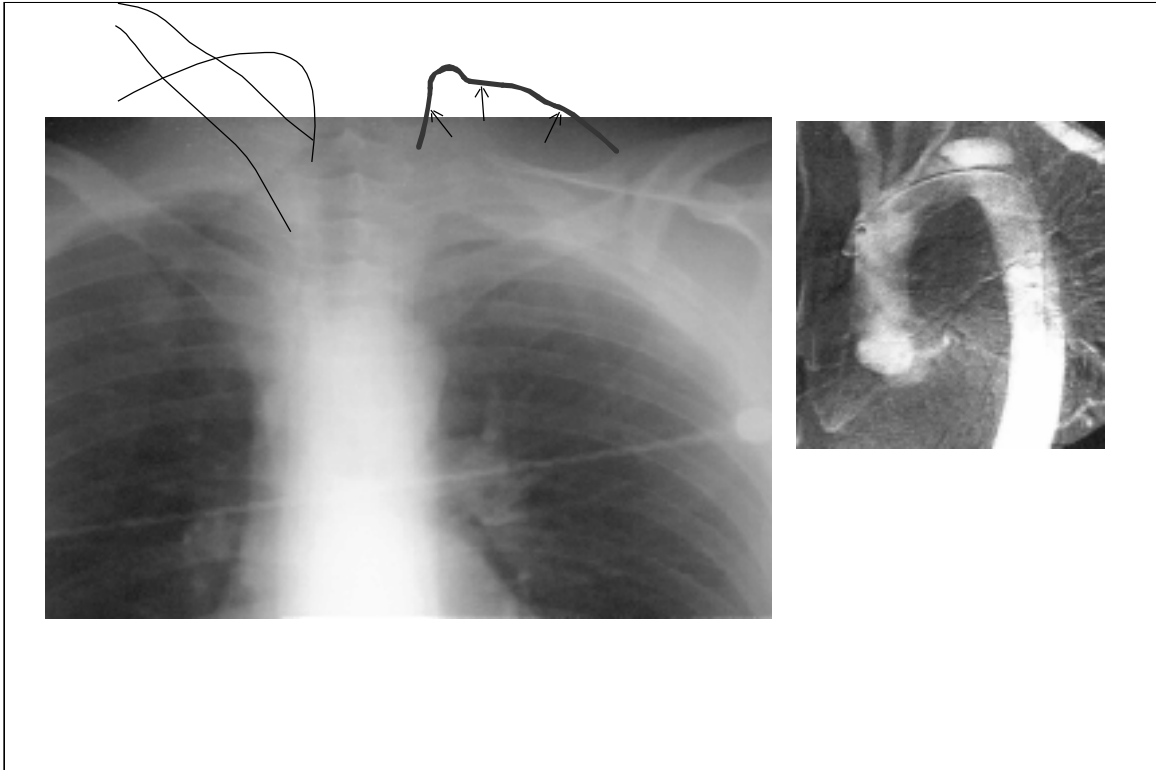


The most common clinical location of injury is the isthmus. In coroner's series the most common location is the aortic root. Unfortunately, most of these victims die at the scene.

Aortic Transection



The signs of aortic injury are nonspecific and relate to the leakage of blood from the laceration.



If any of the signs are present, the patient should undergo a test which actually visualizes the tear, traditionally aortography. Previous authors have noted that an isolated apical cap is not seen with aortic injury. In this example the only abnormality was an apical cap. Remember the chest x-ray is a screen.

Chest x-ray screen

Positive predictive value 10%

Negative predictive value 98%

Too many false positives

The absence of signs of aortic transection virtually excludes injury. The problem with the chest radiograph is the large number of false positive films which leads to a large number of aortograms.

Role of CT

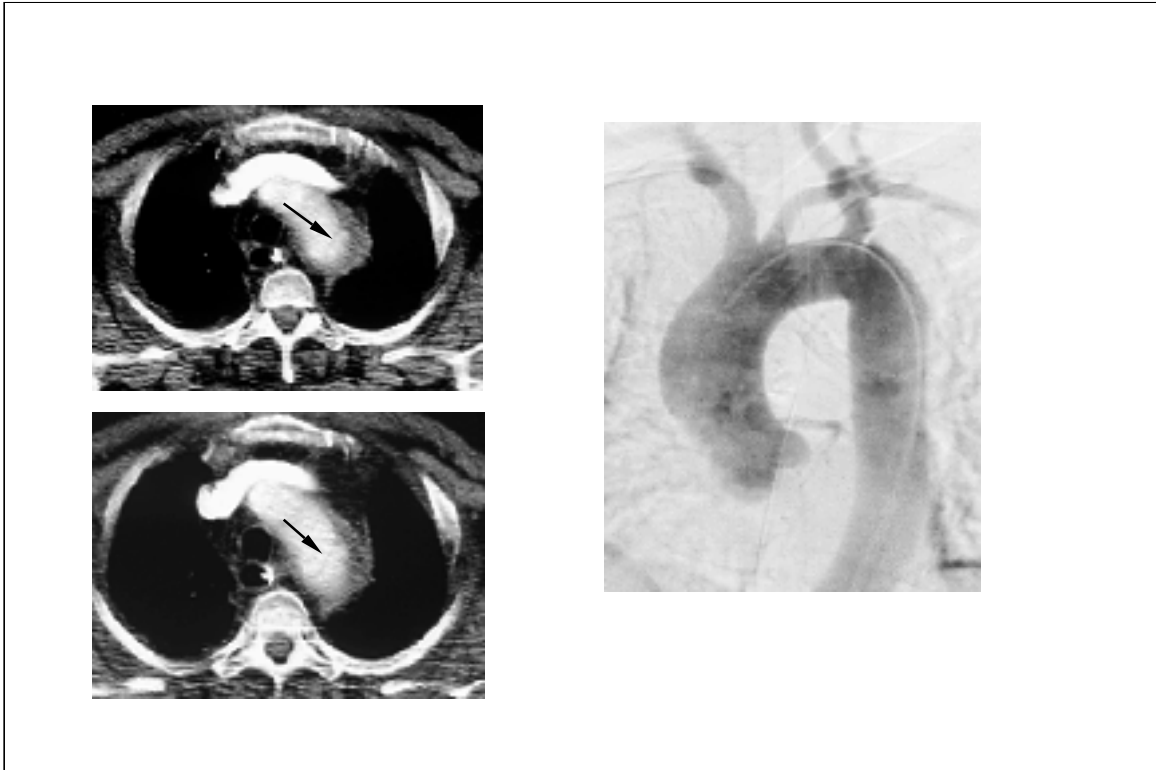
Triage patients for aortogram

160 Deceleration Injury

132 Normal CXR	28 Abnormal CXR
0 CT+	7 CT+
0 Transection	1 Transection

Morgan Radiology 1992

CT has been used as a tool to reduce the number of normal aortograms. Abnormal chest radiographs may be due to other causes such as fat or tortuous vessels. In this older study, the number of patients that needed to be evaluated could be decreased by 1/4th with the use of CT.



With the introduction of spiral CT, investigations have been done using CT as the primary method to diagnose aortic injury. In this case note the periaortic hematoma and the flap in the lumen. Aortography in three plains was unsuccessful in demonstrating the injury which was later confirmed at surgery.

Direct Signs

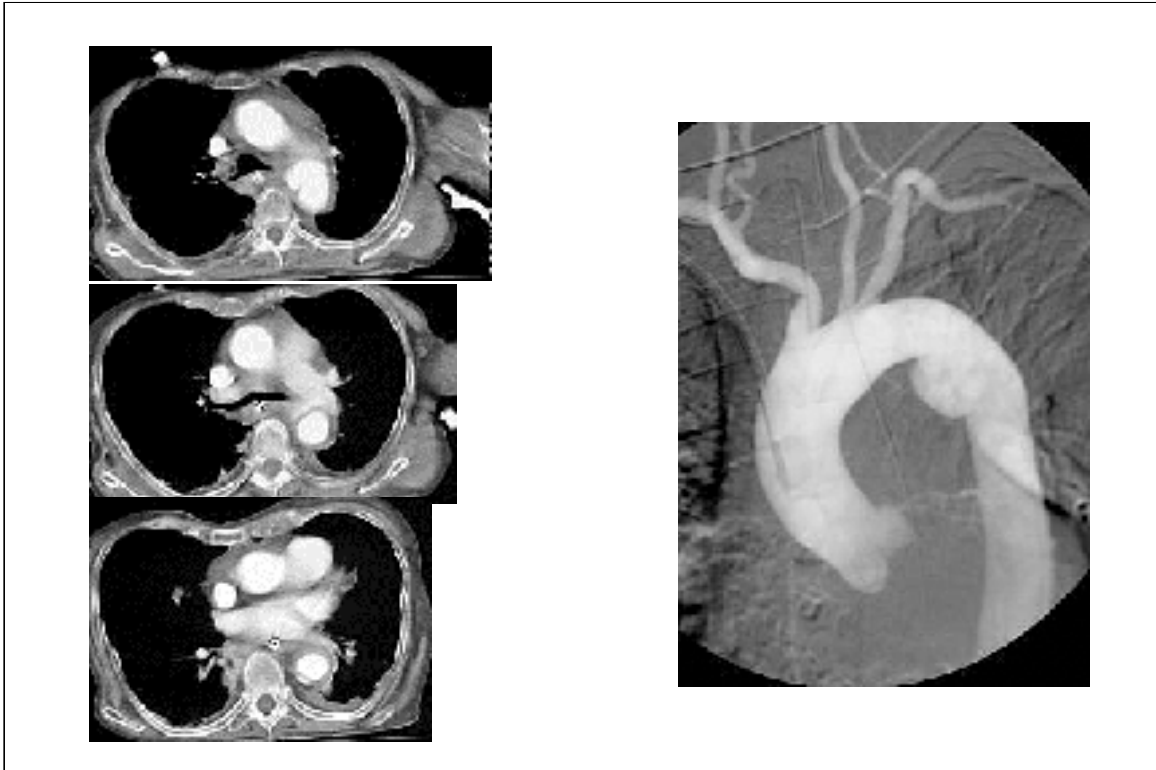
Caliber change aorta

Intraluminal irregularity

Abnormal contour

(Perivascular hematoma)

These are the direct signs of aortic injury at CT. We will return shortly to the sign of perivascular hematomas.



Notice the direct signs of aortic injury in this example.

CT: Aortic Transection

	Gavant Radiology 1995	Dyer Radiology 1999
Study	1 yr ~1500	4 yr ~1000
Aortic transections	18 (1%) 5 branch injuries	10 (1%) no branch
Technique	7 mm 1:1 3.5 recons 2ml/sec	5 mm 1:1
Direct signs	13%	10%
Sensitivity	100 (82-100)	100 (69-100)
Specificity	82 (73-88)	89 (86-92)

Let's compare and contrast two studies using CT in the direct diagnosis of aortic injury. Note the difficulty of performing these studies. Because aortic injury is uncommon it takes a large number of patients to accumulate a small number with injuries. The scanning technique differed in both studies. In both, the sensitivity of CT was 100%, no case was missed. The confidence intervals were not reported in the original articles but have been calculated here. It is important to recognize the small numbers: 18 patients with aortic injury in Tennessee and 10 in Colorado. In fact at the University of Colorado between the time of submission and publication of the article an 11th case occurred without a direct sign. It did have a perivascular hematoma, which was why it was highlighted in parenthesis earlier. With small numbers it is important to calculate confidence intervals for rates and proportions like sensitivity.

Aortography: Gold Standard

Sensitivity 94% (73-98)

Specificity 96% (90-98)

Gavant Radiology 1995

Lastly, let's not forget that aortography, the gold standard is not a perfect exam.

Further Data

3 mm 1.5 pitch, 1.5 recons 2ml/sec

Sensitivity 100% (59-100)

Specificity 89% (83-94)

Negative predictive value 100 (97-100)

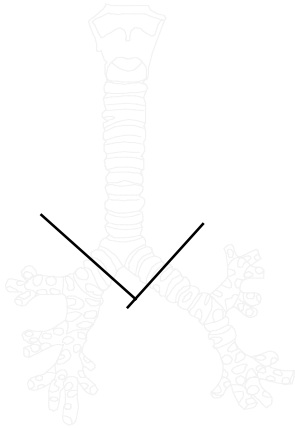
N=142, 7 aortic transections

Parker AJR 2001

Other data for the use of CT comes from the University of Texas Southwestern in Dallas. Again allowing for the small numbers there were no false negatives and the number of false positives was small.



Bronchial Fracture



1.5% major chest trauma

30% missed

80% within 2.5 cm carina

Bronchial tears are uncommon and commonly missed.



This basketball player went undiagnosed with a bronchial tear for 48 hours.

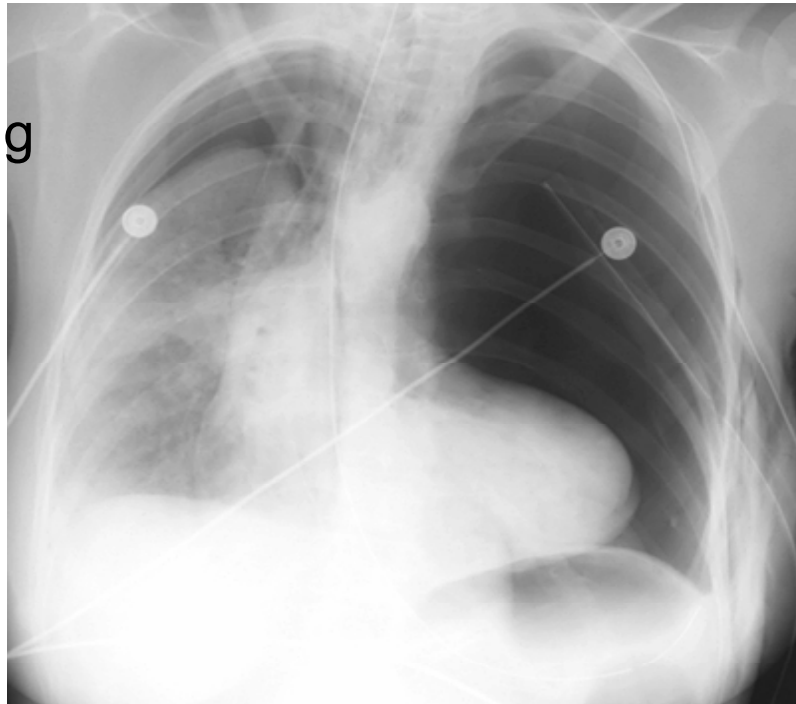Bronchial Tear

P's

Persistent or Progressive Pneumothorax or Pneumomediastinum

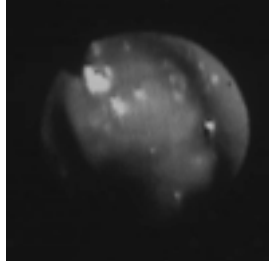
The signs of bronchial tear are nonspecific and due to leakage of air into the pleural space or mediastinum. Since these signs are common, the key is a persistent or progressive pneumothorax or pneumomediastinum.

Fallen Lung



Example bilateral pneumothoraces. The left pneumothorax was treated with a chest tube but the lung remains collapsed - a persistent pneumothorax. The left main stem bronchus was completely fractured. Collapse of a lung into an unusual location is known as the fallen lung sign.

Bronchoscopy



The chest x-ray is a screen. If you suspect a bronchial tear, the next exam is bronchoscopy.



Cord Injury

25% spine fractures

90% neurologic injury



Fractures of the thoracic spine often result in cord injury. The thoracic cord is large in relation to the canal leaving little room for clots or bone fragments.

Facet joint orientation

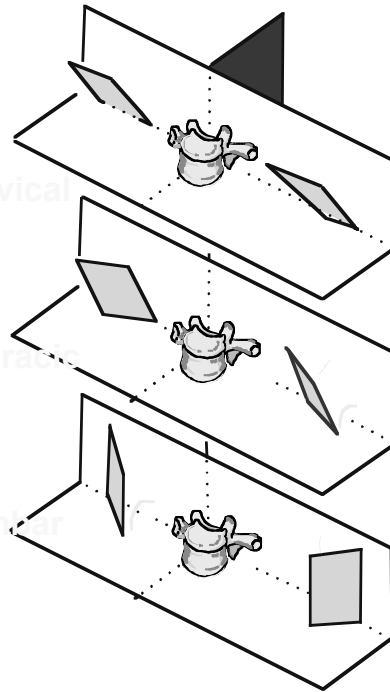
Critical zone

T₉-T₁₁

Cervical

Thoracic

Lumbar



The most common location for a fracture is between T9 and T11. The schematic shows the orientation of the facet joint in the spine.. The thoracic facets face inward and the lumbar facets outward. The weak point is the transition in this orientation which usually occurs between T9 and T11.

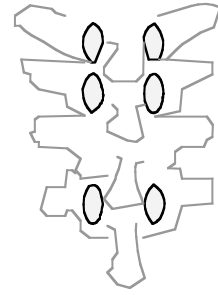
Rule of 2's

No more than 2 mm

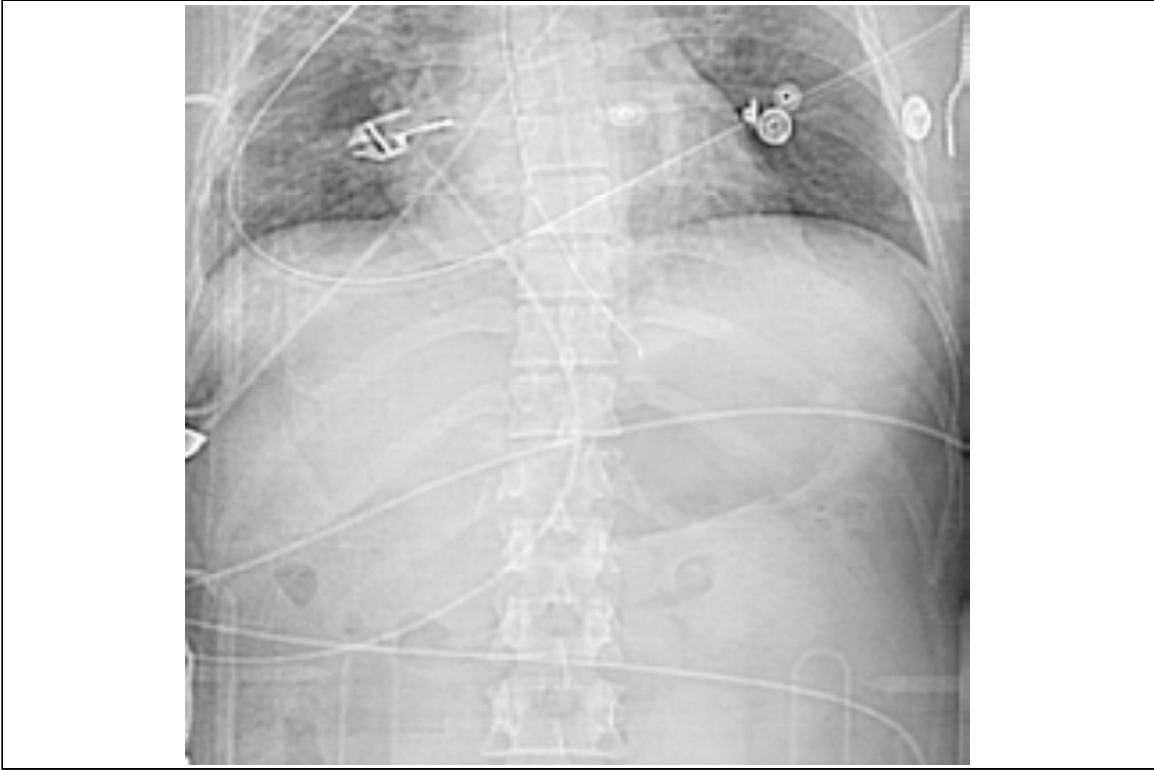
Interspinous space

Interpedicular distance

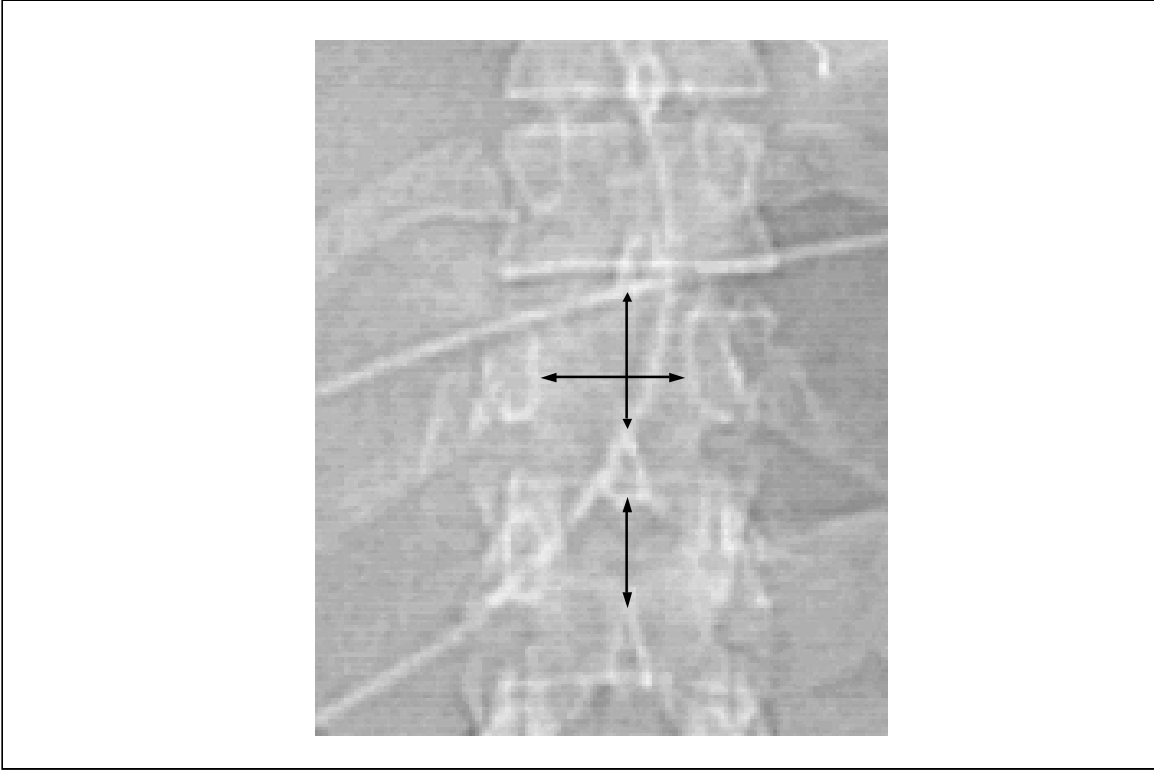
Intrapedicular distance



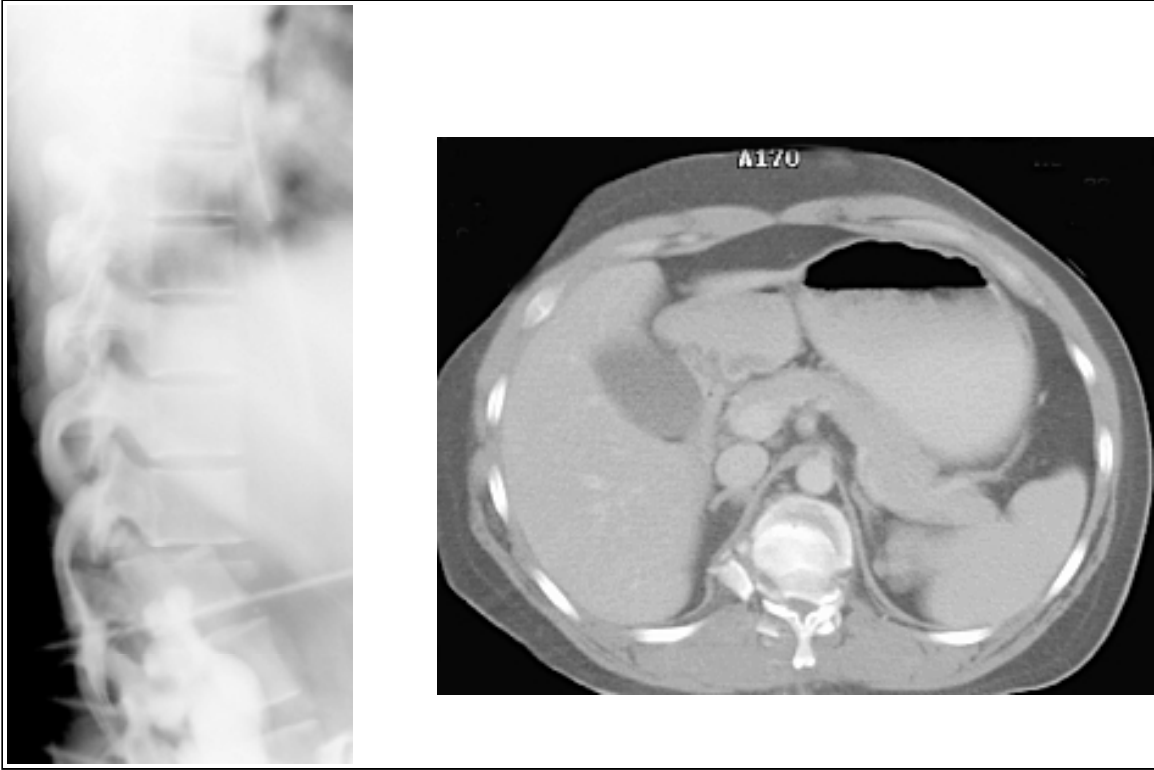
Only the AP view can be evaluated on the chest x-ray. Particular attention should be paid to the pedicles and spinous processes. There should be no more than 2 mm in difference in these distances from one level to the next.



Evaluate the spine in this example. A magnification view is available on the next slide.



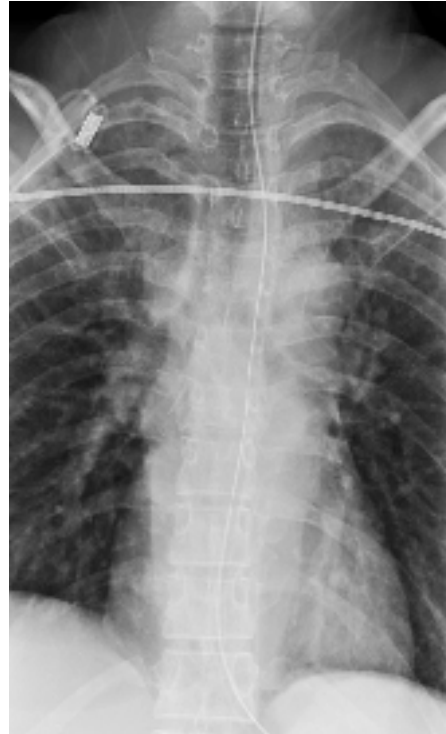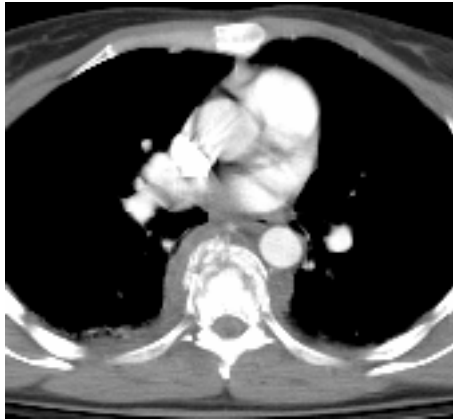Note the widening of these distances at T12.



These subtle findings on the AP view actually represent a severe fracture dislocation with near complete obliteration of the spinal canal.

T Spine Fx

70% simulate Aortic transection



T spine fractures often mimic aortic transection and must be kept in mind when evaluating these individuals.

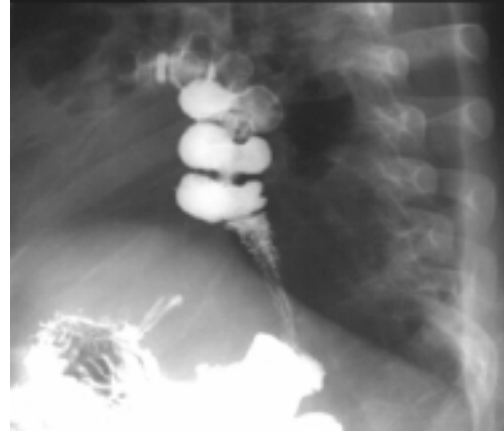


Diaphragm Rupture

5% Blunt chest Trauma

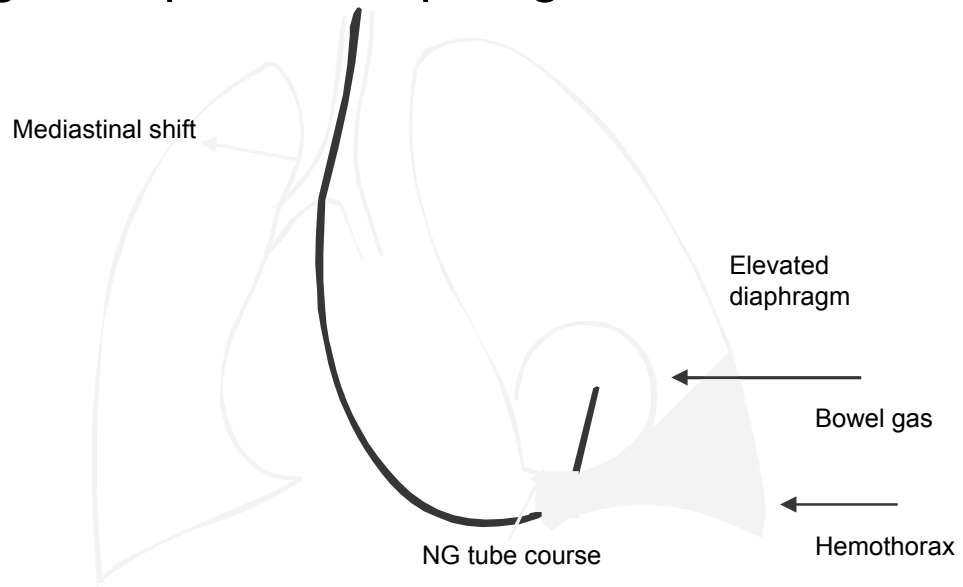
90% left-sided

70% initially missed




Diaphragmatic tears are common and commonly missed. The most common location is the central tendon, extending posterolaterally.

Signs Ruptured Diaphragm



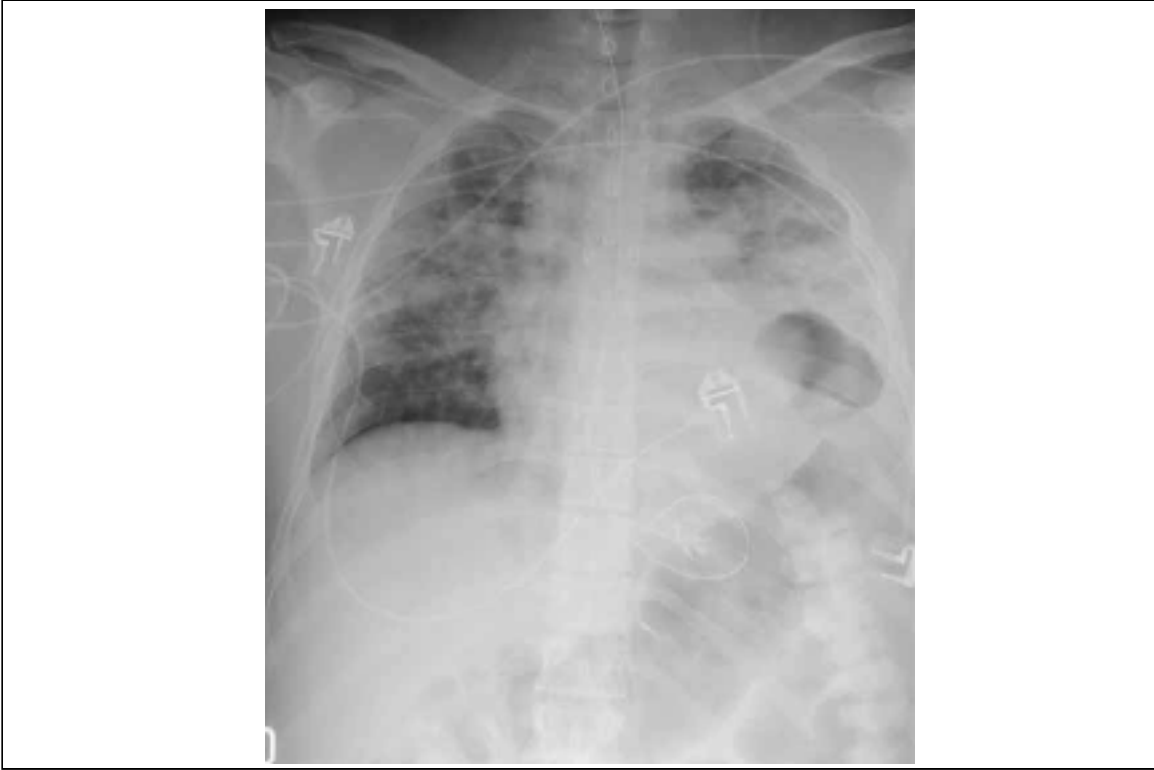Signs are usually nonspecific. Abdominal contents act as a mass and the mediastinum will shift away from the herniation.

Diaphragm Hernia: Barium Exam

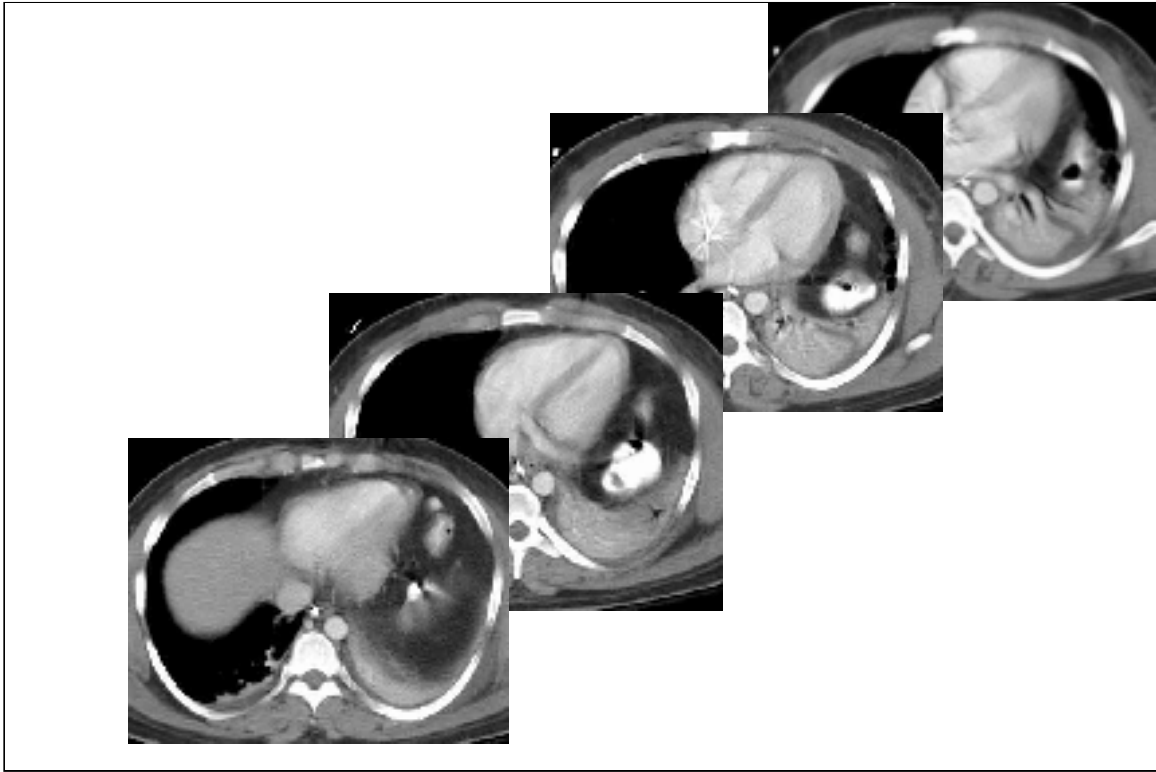


Blatt & Felson 1962

Traditionally barium studies have been used to diagnose tears. Note the collar or constriction of the bowel lumen at the site of the laceration, which Felson called the kissing bird sign. Statistically either the colon or the stomach have about equal likelihood of herniating.



Bowel gas overlays the lower left hemithorax. The mediastinum is subtly shifted to the right.



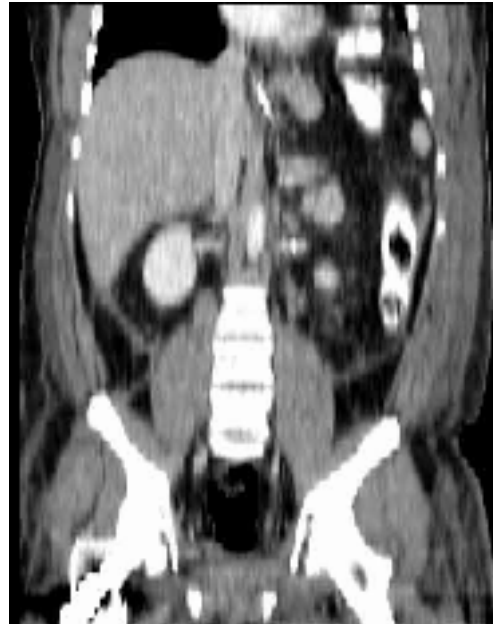Sequential CT was inconclusive for diaphragmatic tear.

CT: Diaphragm

Swine Study

	Sensitivity	Specificity
Sagittal	92	87
Coronal	85	87
Axial	73	80

Israel AJR 1996



3 mm collimation, 1:1 pitch, 2 mm recons

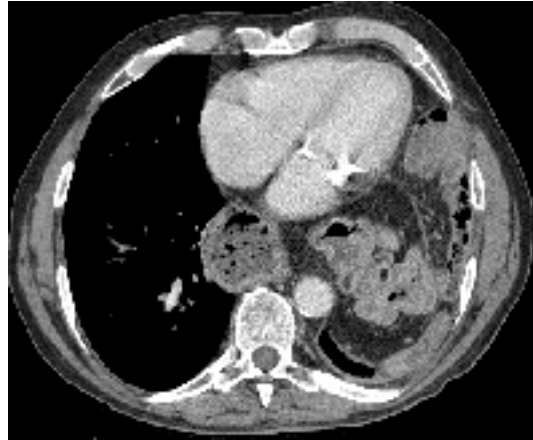Because CT is often used in blunt trauma, of what value is this test in diaphragmatic tears. A swine model using 3 mm collimation and 1:1 pitch was used to investigate this question. Note the large number of false negatives with axial images alone. False negatives are reduced with sagittal or coronal reconstructions. In this example, coronal reconstructions demonstrated the diaphragmatic hernia.

Dependent Viscera sign

Sensitivity

100% left (4/4)

83% right (5/6)



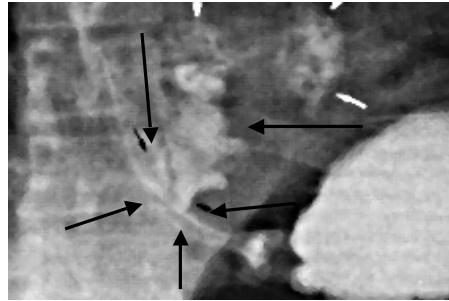
Bergin AJR 177: 2001

One other useful clue for diaphragmatic injury in the dependent viscera sign. Bowel or organs normally do not contact the ribs due to the separation by the normal diaphragm. Contact is known as the dependent viscera sign.



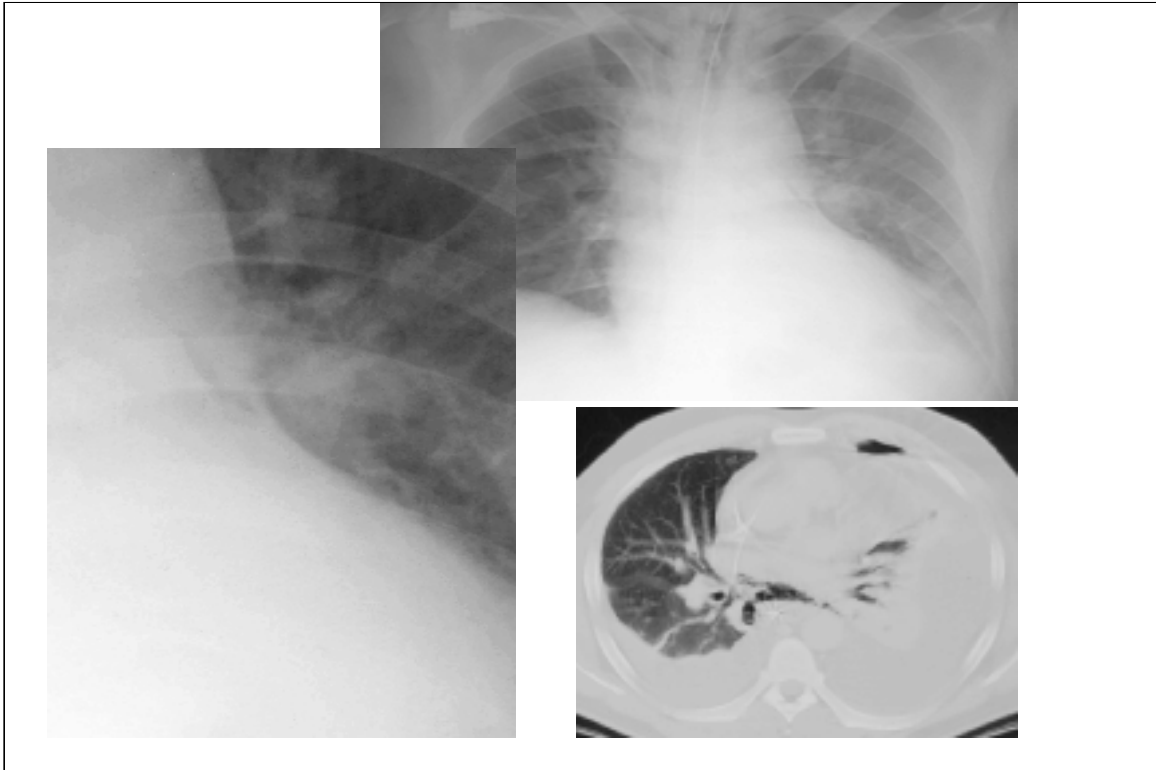
Esophageal Perforation

Boerhaave's syndrome
Increased esophageal pressure



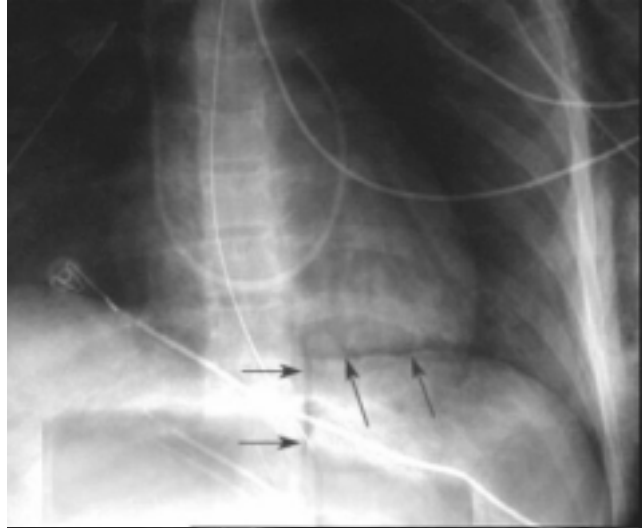
Left
Linear, vertical tear
Posterolateral wall

Esophageal tears are a rare injury. The most common location is the upper esophagus.



In this example, a tiny pneumomediastinum was present along the upper left heart border. At CT note the air surrounding the esophagus in this proven tear.

V sign Naclerio



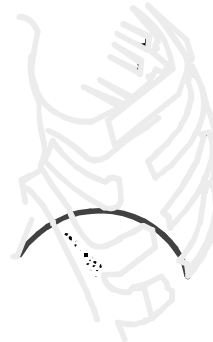One tip off to esophageal injury is the presence of air in the costovertebral angle. Air along the diaphragm and paravertebral air forms a "V". Once an injury is suspected the next proper exam is an esophogram with nonionic contrast. CT is also useful to show air surrounding the esophagus.



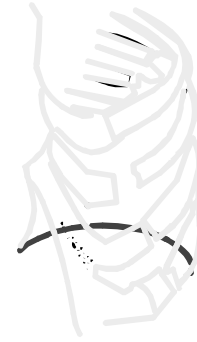Flail Chest

5 adjacent rib fxs

> 3 segmental fxs

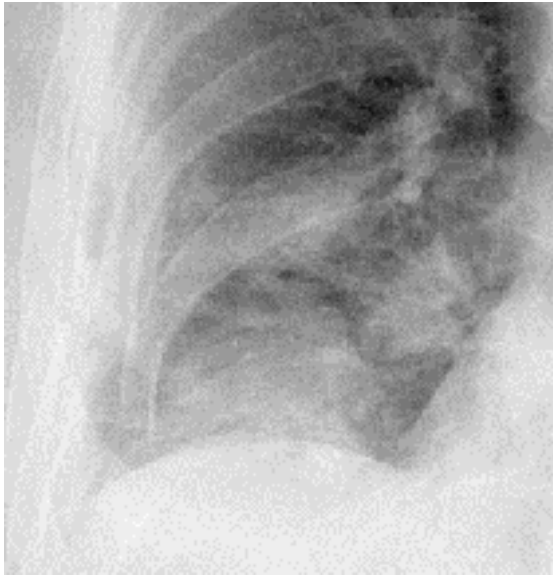

Expiration




Inspiration

The flail chest is associated with significant morbidity. Paradoxical motion of the chest wall impairs ventilation. This injury should be suspected in those with 5 adjacent rib fractures or 3 adjacent segmental fractures.



Costal Hook Sign



Jackson Eur J Rad 1991

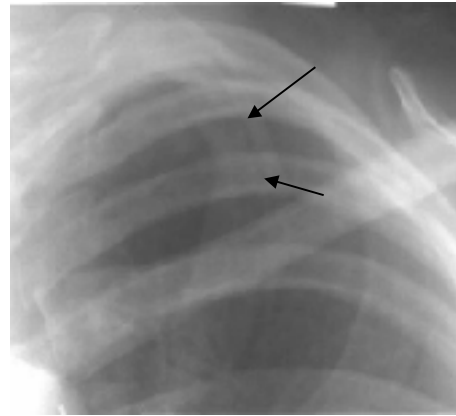
Segmental rib fractures will rotate into a configuration known as the costal hook sign. To me they look like elephant trunks.

First Rib Fracture

Aortic injury 20%

Bronchial fracture 80%

Mortality 20%



The first rib is well protected and requires a significant force to fracture and thus is a marker of the severity of trauma. The associations listed here reflect that.



Gas (Pneumo)

15 - 40 % of patients

Subtle signs supine CXR

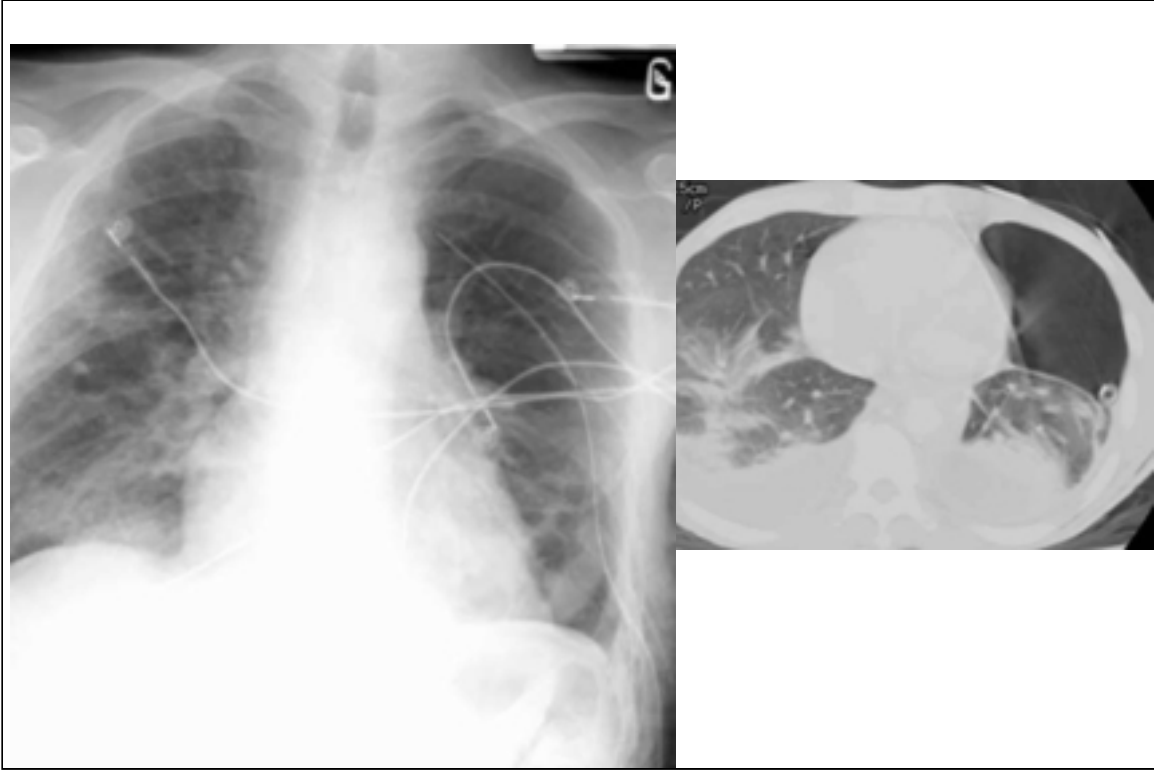
Deep sulcus

Sharp cardiac borders

Basilar hyperlucency

Visualize pericardial fat tags

Gas collections are common. In the supine film the signs of pneumothorax may be subtle.



In this example, a large pneumothorax on the left was missed. The left hemidiaphragm and mediastinal contours are sharper than on the right and were subtle clues for the presence of the pneumothorax. We were all surprised at how large the pneumothorax was at CT.



Heart Injury

Myocardial contusion 50%

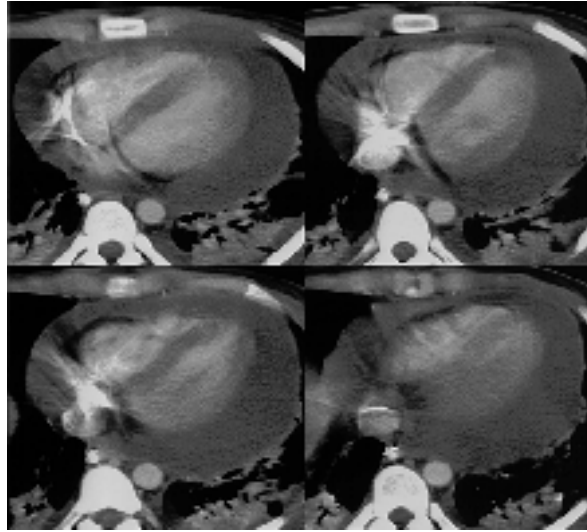
Less common

pericardial laceration

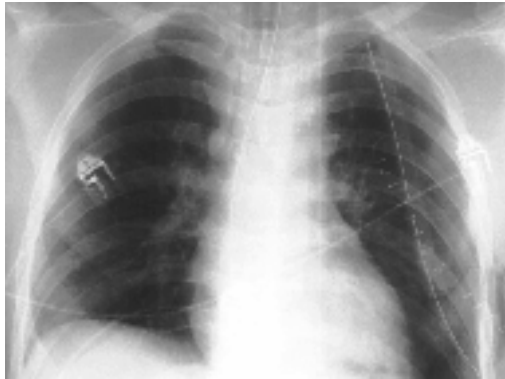
myocardial rupture

aortic valve rupture

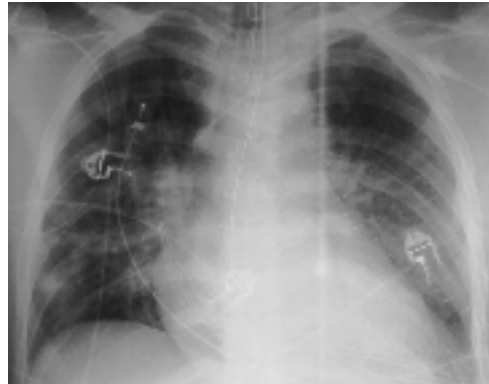laceration coronary artery



Cardiac contusions are common. Other injuries are much less common.



Initial



3 days later

One should suspect a cardiac injury in any patient with an enlarged heart or the sudden development of pulmonary edema. Both signs evident in this patient. Again the chest x-ray is a screen and the next proper test is echocardiography. On the previous slide the patient had a CT which demonstrated a hemopericardium. This example also highlights the importance of applying the ABC's to every film. Some of these injuries may be delayed and will not be present on the initial examination.



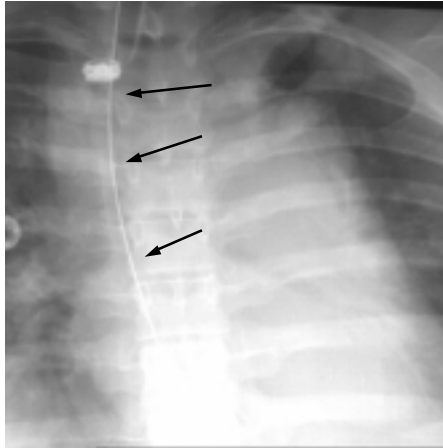
Malpositioned Tubes & Catheters

Tube	Desired Position	Common Malposition
ET	Trachea	Esophagus, Mainstem
Catheter	SVC	Pleural space, artery
NG	Stomach	Bronchus
CT	Pleura	Chest wall

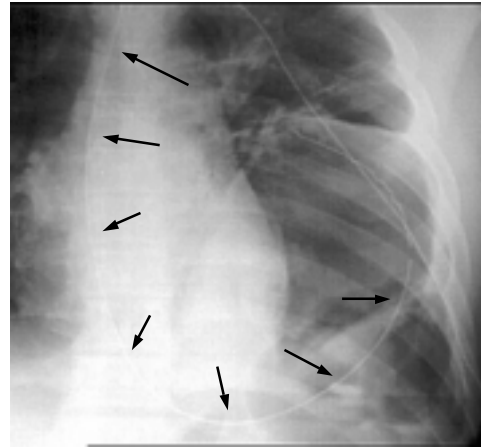
Lastly malposition of tubes and catheters is common.

NG Tube Course

Aortic tear

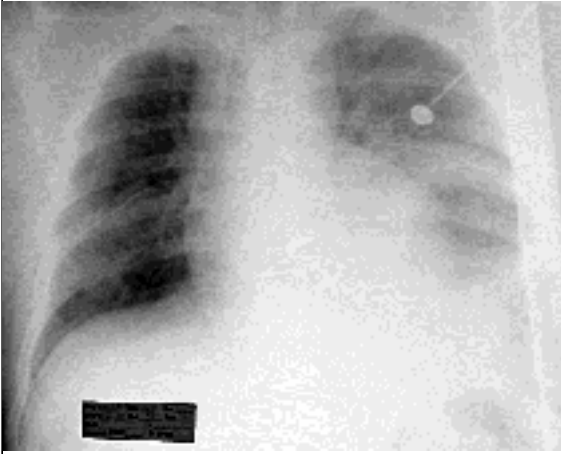


Diaphragm tear

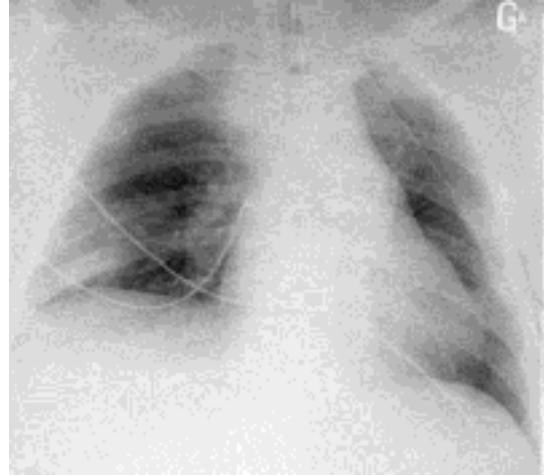


The course of the NG tube is helpful in diagnosis.

ABC...

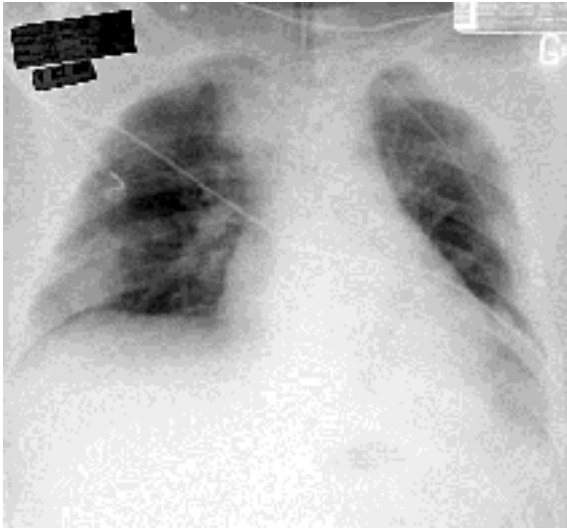


Initial

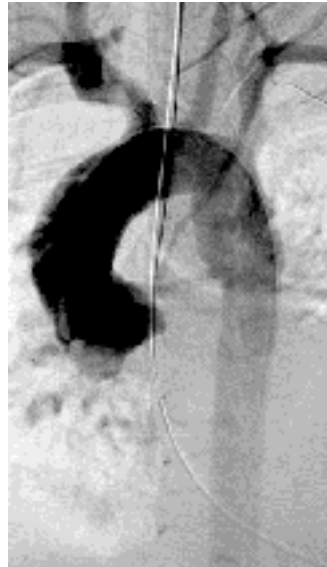


11 hours later

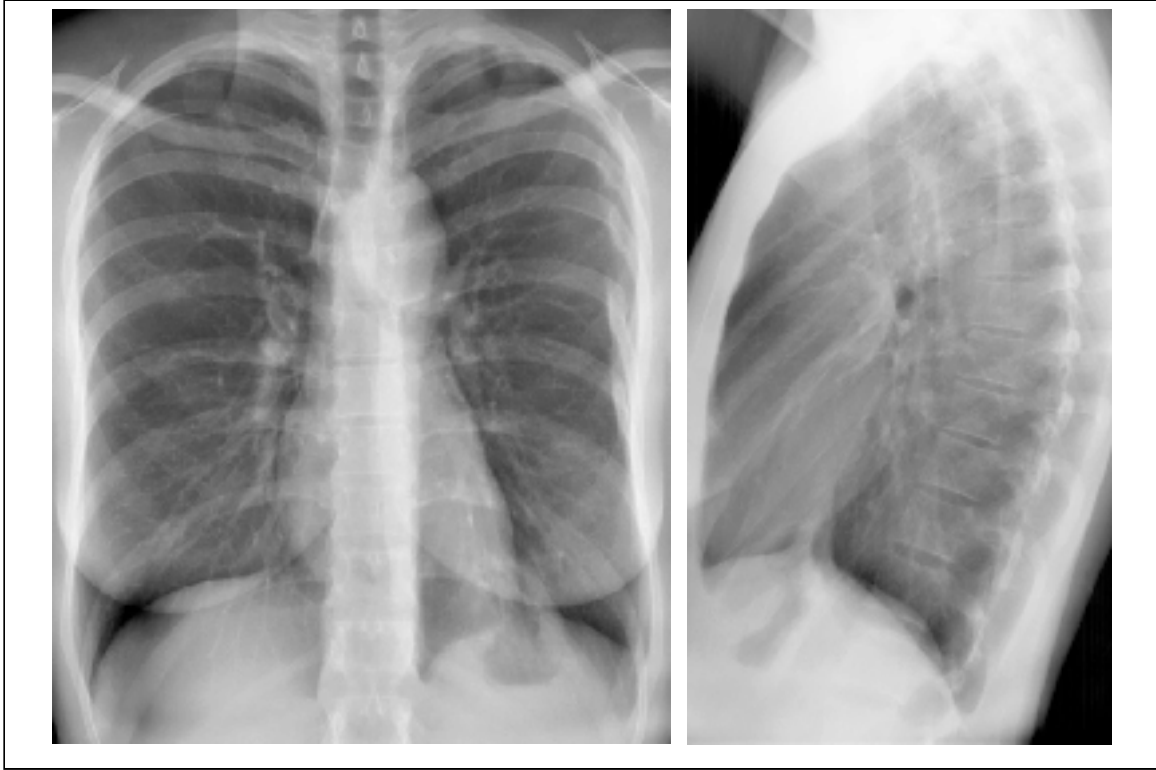
Let's do the ABC's. Everyone saw the left diaphragmatic tear.
Any other problems?



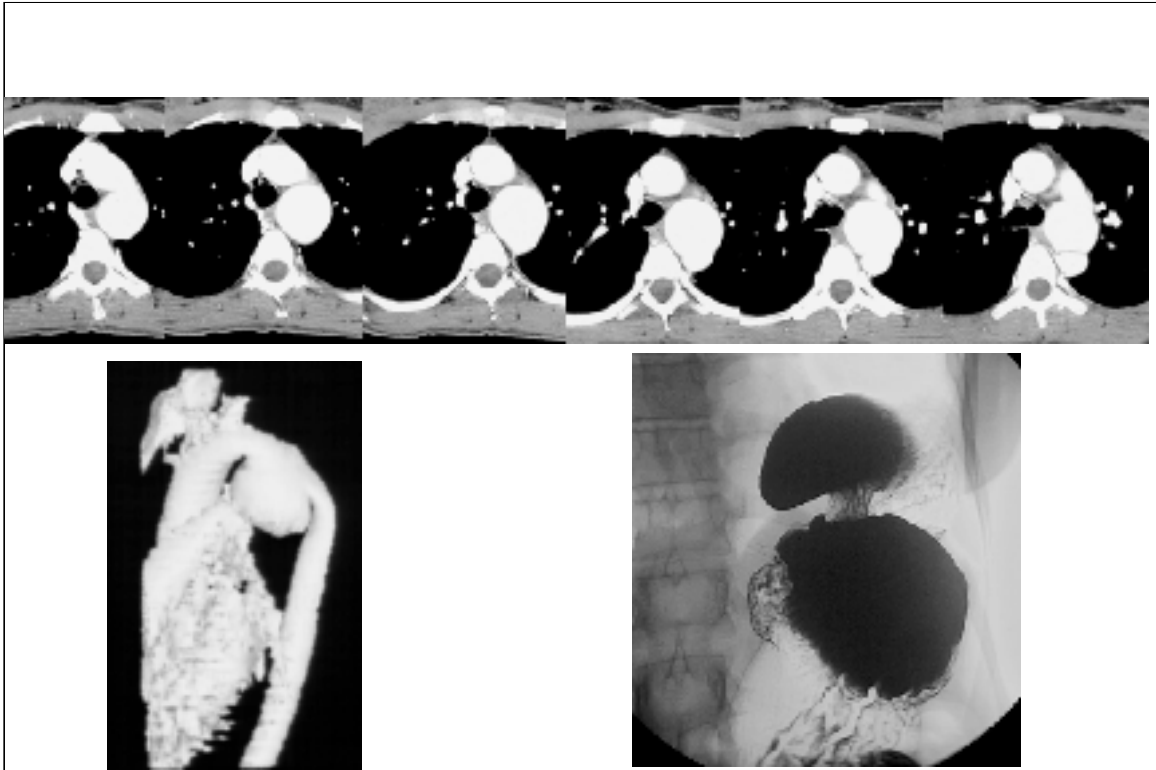
4 days later



4 days later a new radiologist, me, thought the mediastinum was wide on all the films - an angiogram shows the pseudoaneurysm.



Final example, an outpatient with chest pain. Note the multiple healed left rib fractures. Do the ABC's.



A was abnormal. CT and 3D reconstructions nicely show the transection. Did you finish the ABC's? D was also abnormal, note the collar sign of the stomach as it herniates into the chest.

Screen!

A: Aortography

B: Bronchoscopy

C: CT

D: Drink barium

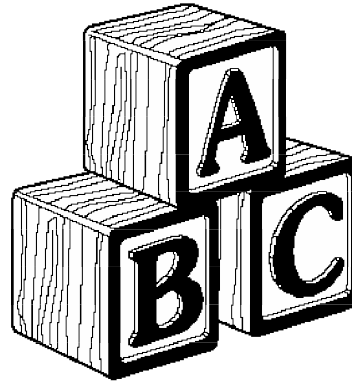
E: Esophogram

F:

G: CT upright or decubitus films

H: echocardiography

I: Inject



Remember the chest x-ray is a screen. Follow-up exams are needed either to diagnose or exclude injury.



*“Now you know your ABC’s
won’t you please save lives with these”*



Now you know your ABC’s, won’t you please save lives with these.